

## Supraorbital Keyhole Approach for Anterior Circulation Aneurysms - A Report of 11 Cases

Dr.Gaurav Rai Sharma<sup>1</sup>, Dr.Naresh Krishnani<sup>1</sup>, Dr.Bhagwati Salgotra<sup>1</sup>,Dr.Atul Rai Sharma<sup>2</sup>, Dr.Anchal Malhotra<sup>3</sup>

<sup>1</sup>(Neurosurgery, SBKS Medical College/ Sumandeep Vidyapeeth University, India)

<sup>2</sup>(Orthopaedics, MM Institute of Medical Sciences and Research, India)

<sup>3</sup>(Microbiology, Dayanand Medical College and Hospital, India)

---

### Abstract

**Introduction:** Many different conventional approaches, such as frontal and pterional approach are used to access anterior circulation aneurysms. These approaches provide excellent exposure to anterior and middle crania fossa. The major limitation of these approaches is extended openings to expose the orbital rim. In recent decades, development of surgical instruments and microsurgical skills allows neurosurgeons to use smaller and more specific approaches to treat these lesions in the same region. One of these approaches, supraorbital subfrontal craniotomy offers a minimally invasive approach to a variety of lesions. Supraorbital craniotomy has been shown to be effective and safe for anterior circulation aneurysms. This approach has the advantages of less operative time and less retraction for brain tissue. Along with this rationale, we present our experience in clipping 11 anterior circulation aneurysms here.

**Patients and Methods:** Out of a series of 11 patients harbouring 11 anterior circulation aneurysms operated on via a supraorbital keyhole approach with a superciliar or front wrinkle skin incision. Data on patient's medical records, intraoperative and postoperative complications and surgical outcomes of patients were collected and reviewed.

**Results:** There was a good cosmetic results with less approach-related complications. Successful clipping was obtained in 100% of patients, Good Glasgow Outcome Scale scores of 4 or 5 were achieved in 72.7% of the patients at the time of discharge. CSF leak was observed in 2 patients.

**Conclusion:** The supraorbital route is recommended for selected anterior circulation aneurysms based on the improved surgical instruments and microsurgical skills.

**Keywords:** Anterior circulation aneurysms, eyebrow incision, keyhole surgery, supraorbital keyhole approach, transciliary supraorbital keyhole.

---

### I. Introduction

Many different conventional approaches such as frontal and pterional approach are used to access anterior circulation aneurysms. These approaches provide excellent exposure to anterior and middle crania fossa. The major limitation of these approaches is extended openings to expose the orbital rim. The evolution of these approaches from Dandy's frontotemporal "macrosurgical approach" to Yasargil's microsurgical pterional approach and finally to the supraorbital keyhole approach through an eyebrow incision all have served to give the neurosurgeon the exposure they needed to safely address various pathologies.<sup>[1]</sup> Keyhole surgery for intracranial lesions has shown how a seemingly small incision ('band-aid' incision) can be adequate for operating on tumours and aneurysms. Complications such as chewing discomfort occur less frequently in the supraorbital approach. Moreover, the cosmetic outcome is significantly better in this approach.<sup>[2]</sup> The goal of "keyhole" surgery was not to perform a small incision and craniotomy for the sake of a small opening. The goal of this approach was to permit adequate access to skull base lesions while limiting trauma to surrounding structures such as the skin, bone, dura and most importantly, the brain.<sup>[3,4]</sup> Surgery through an eyebrow incision may not be appropriate for all lesions of the anterior skull base. There is a narrow viewing angle through this approach that may require frequent adjustment of the operating room table and microscope for adequate visualization of a given lesion. The microscope light is often another problem as there may be some difficulty getting adequate light through such a small opening onto a deep-seated lesion.<sup>[2,5]</sup> In the setting of vascular lesions, a smaller opening in a blood-filled field can also make it difficult to obtain adequate vascular control without damage to surrounding structures.<sup>[6]</sup> Relative contraindications include the presence of a large frontal sinus, severe brain oedema and recent subarachnoid haemorrhage.<sup>[7]</sup>

Refinements in operative technique have led to almost all aneurysms of anterior circulation being amenable to clipping by supraorbital keyhole approach. Supraorbital craniotomy has been shown to be effective and safe for anterior circulation aneurysms. This approach has the advantages of less operative time, less retraction for brain tissue with a similar rate of complications related to the surgical treatment of anterior

circulation aneurysms when compared with conventional approaches.<sup>[5]</sup> Along with this rationale, we present our experience in clipping 11 anterior circulation aneurysms in a tertiary care hospital.

## **II. Surgical Description**

After general anaesthesia, endotracheal intubation and placement of a Foley catheter, the patient is fixed in a Mayfield three-pin head holder with two pins on the ipsilateral posterior cranium and the one pin site on the contralateral frontal bone. The torso is slightly elevated at ten degrees, and the head is positioned in a slightly extended position of around 15–20 degrees to allow gravity retraction of the frontal lobes away from the surgical field. No retractors are used. The head is turned approximately 15–45 degrees contralaterally to the side of surgery to allow appropriate visualization of midline lesions. Steps of this approach: A small (4–5 cm) long eyebrow incision is made and the pericranium is separated. Thereafter a small basal orbital roof craniotomy (measuring 2 cm by 3 cm), including the supraorbital arch, is made as a single piece bone flap using a craniotome. The orbital roof is then opened up to the supraorbital fissure and to the optic canal by additional removal of bone in the orbital roof. This will expose the globe and the orbitofrontal dura mater. When the dural incision is made at the orbital portion of the dura mater, the orbital contents are retracted by tack-up sutures. The microscope is brought into the field, the frontal lobe is lightly retracted with a cottonoid, and the CSF cisterns are opened to allow CSF egress to facilitate brain relaxation. Following brain relaxation, the primary procedure may be performed safely with no fixed retractors on the brain and with use of the operative microscope, a rigid rod-lens endoscope, or both. The surgery is carried out utilising the orbital space rather than the intracranial space. The direct eyebrow incision provides an additional vital working space with a width of more than 1 cm at the skull base by eliminating the scalp flap which a coronal incision employs.<sup>[8]</sup> Wound closure is straightforward. The dural leaflets are reapproximated with a 4-0 Nurolon suture sewn in a running fashion. The craniotomy bone flap is replaced with a titanium burr hole cover and two titanium square plates to improve the cosmetic result by restoring the supraorbital ridge. The pericranium and muscle flap are then closed primarily. Buried, interrupted, and absorbable sutures are used in the dermis and a 5-0 prolensubcuticular stitch is placed without any knots to ensure removal in the office in 7–10 days.

Here, we describe our preliminary experience with the supraorbital keyhole approach for the clipping of anterior circulation aneurysms.

## **III. Patients And Methods**

### **3.1 Clinical Material**

Between November 2014 and December 2015, all consecutive 11 patients with anterior circulation aneurysms were treated. Data on patient's medical records aneurysms characteristics, intraoperative and postoperative complications and surgical outcomes of patients were collected and reviewed. The supraorbital keyhole approach performed in this study was described in detail by Perneczky *et al.*<sup>[4]</sup> The patient was placed in the supine position. The head was elevated above the level of the heart and turned between 15° and 60° to the contralateral side of the intended incision. The extent of head rotation depended on the location of the lesion. For ipsilateral MCA lesions, 15° of head rotation was used for lesions of the communicating segment of the internal carotid artery (ICA), 20-30° of head rotation has been found to be sufficient. Surgery of the anterior communicating artery required a rotation of 40-60°. The neck of the patient was slightly retroflexed so that the zygomatic arch was the highest point. This position allows the gravity related self-retraction of the frontal lobe. After sterilizing the eyebrow region, a standard skin incision was made in the superior edge of the eyebrow or on the forehead crease just above the eyebrow, starting from the midpupillary line and extending laterally to just behind the frontal process of the zygomatic bone. The supraorbital nerve and artery, the frontal branches of the facial nerve, and the superficial temporal artery were always preserved. Subcutaneous dissection was performed from the supraorbital foramen to the frontozygomatic suture. The temporalis fascia was incised a few millimeters before its insertion at the anterior temporal line. The keyhole was exposed via subperiosteal dissection of the temporalis muscle. A burr hole was drilled on the superior temporal line, just above the frontal base. The craniotomy was performed using a high-speed drill. The medial-inferior edge of the craniotomy went around the level of the frontal base and the lateral edge to the sphenoid wing, at a width of 25-30 mm and a height of 15-25 mm. A large frontal sinus is a relative contraindication to this approach. If the frontal sinus was entered, it was exenterated by stripping and cauterizing its mucosa. The sinus was then covered with a periosteal flap. The dura was opened in a semicircular fashion. A conventional microsurgical technique was used with optimal illumination with an operative microscope. The arachnoid of the carotid cistern, the Sylvian fissure, and suprasellar cisterns were opened for CSF drainage, to create enough room for brain retraction and surgical manipulation. To increase CSF drainage, the membrane of the lamina terminalis was sometimes opened. At the end of the operation, a watertight dural closure was obtained using silk suture and fibrin glue. The temporalis muscle and fascia were sutured to the frontal pericranium. The skin was closed layer by layer.

## IV. Results

### 4.1 Surgical Findings

Three patients with nonruptured aneurysms were clipped on the day of admission. For those 8 cases with ruptured aneurysms, 7 were performed on day 1- 3. In another patient, the clipping was performed 12 days after rupture. The size of the aneurysms was between 5 and 19 mm. A temporary clip was used in 10 patients with an average time of 4.5 minutes. Intraoperative rupture was not experienced.

### 4.2 Clinical Outcome and Complications

Postoperative angiography was performed on all patients, demonstrating that successful and complete clipping was achieved in all patients (100%). All patients were discharged in a satisfactory condition. Out of 11, 8 patients (72.7%) achieved good Glasgow Outcome Scale scores of 4 or 5. None of the patients developed neurological deficit. 2/11 (18.2%) patients developed a cerebrospinal fluid leak, both of which underwent spontaneous cure. Secondary seizures occurred in 1 patient which was controlled by anti-seizure medication.

There were few approach-related complications. One patient experienced permanent partial supraorbital hypesthesia as a result of lesion of the supraorbital nerve, but there was no depression of the operated site and palsy of the frontal muscle. There was no frontalis branch palsy of the facial nerve. Wound healing disturbances were not observed.

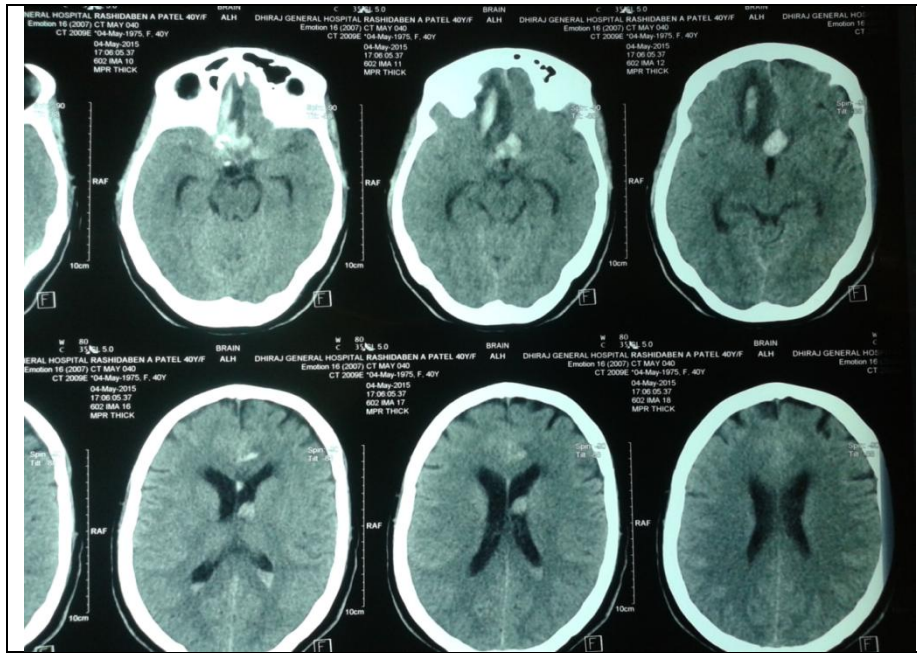
## V. Discussion

Since intracranial aneurysms will continue to be clipped for times to come, the concept of minimally invasive keyhole approach for anterior circulation aneurysms should remain within the armamentarium of neurosurgery. The transciliary supraorbital keyhole approach can be regarded as a standard for clipping of various anterior circulation aneurysms. Compared to standard craniotomy, incision is small, there is a smaller bone window with requirement for distinct microneurosurgical techniques and instrumentation and the approach can be combined with neuroendoscopy.<sup>[1]</sup>

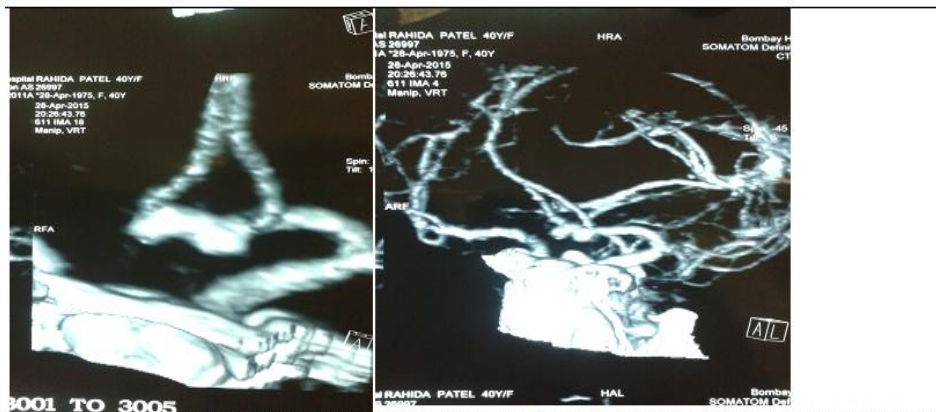
A neurosurgeon graduates to minimalism he becomes familiar with the microanatomy of the region concerned. One common objection to key-hole concept is the limited access and scope for maneuverability during aneurysm dissection. The key to the problem is a thorough familiarity with microanatomy learned on cadavers. One evolves with the procedures as much as the procedure evolves over a period of time. Case selection is certainly important, as is a critical self-appraisal of one's ability to work in narrow, confined spaces. Introduction of tube-shaft instruments for dissection and clip application has made this procedure possible. Wide opening of arachnoid spaces, including Sylvian fissure is mandatory to achieve relaxation of the brain, and passage to the aneurysm location.<sup>[9]</sup> Retraction is less than what is made in a standard craniotomy. We have been able to preserve olfaction without having to dissect the olfactory tract in all of our patients. None of our patients had to undergo osteotomy of the orbital rim or drilling of anterior clinoid. Dare *et al* reported on the successful use of this procedure in elective surgery of 10 aneurysms of the anterior circulation. The mean aneurysm size was 5.9 mm, with a range of 4–10 mm. They highlighted the advantages of this approach that include minimal disruption and exposure of normal brain tissue, reduced frontal lobe retraction and an excellent post-operative cosmetic result.<sup>[6]</sup> Similarly none of our patients had post-operative neurological deficit and all of them had good cosmetic outcome.

## VI. Conclusion

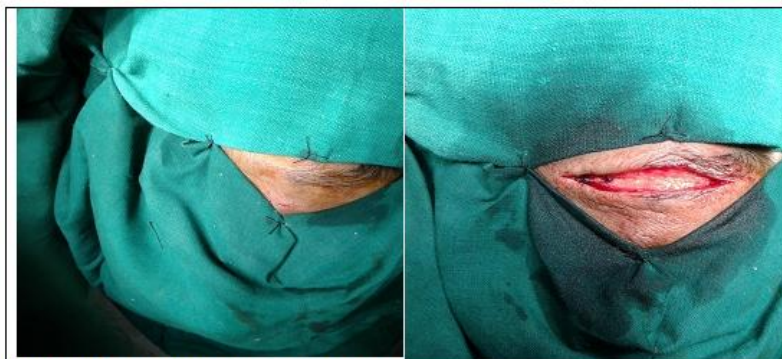
The transciliary supraorbital keyhole approach can be regarded as a standard for clipping of various anterior circulation aneurysms. Compared to standard craniotomy, incision is small, there is a smaller bone window with requirement for distinct microneurosurgical techniques and instrumentation, and the approach can be combined with neuroendoscopy. Nevertheless, this approach cannot be a standard approach for all lesions, it can be applied to only very special aneurysms with an intense pre-op evaluation and in very skilled hands, the decision to approach these aneurysms by supraorbital craniotomies should be based on aneurysms features, size, growth pattern, and the surgeon's experience.



**Figure 1: C.T SCAN OF A PATIENT WHICH REPORTED SUB ARACHNOID HAEMORRHAGE WITH ANTERIOR INTERHEMISPHERIC HAEMATOMA WITH BASIFRONTAL HAEMATOMA EXTENDED TO VENTRICLE (FISHER GRADE 4)**



**Figure 2: CT ANGIOGRAPHY OF A PATIENT SHOWING S/O BILOBED A-COM ANEURYSM, LEFT SIDE DOMINANT A1 AND HYPOPLASTIC LEFT A1.**



**Figure 3: PRE-OPERATIVE PICTURE OF PATIENT**

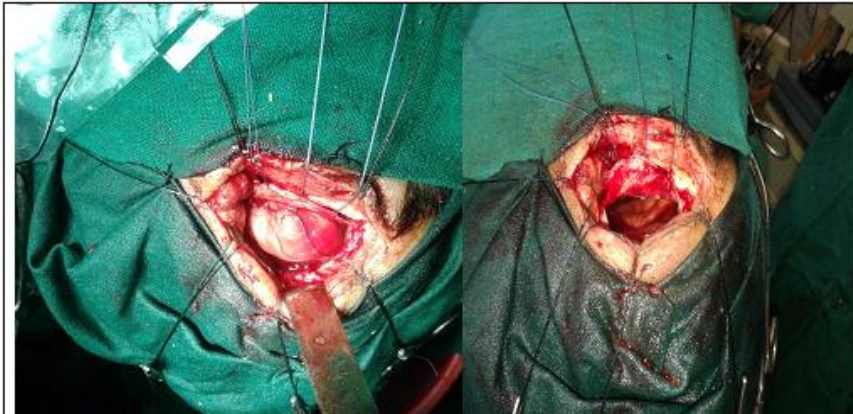

Figure 4.1: BRAIN WITHOUT RELAXATION

Figure 4.2: RELAXED BRAIN WITHOUT RETRACTORS

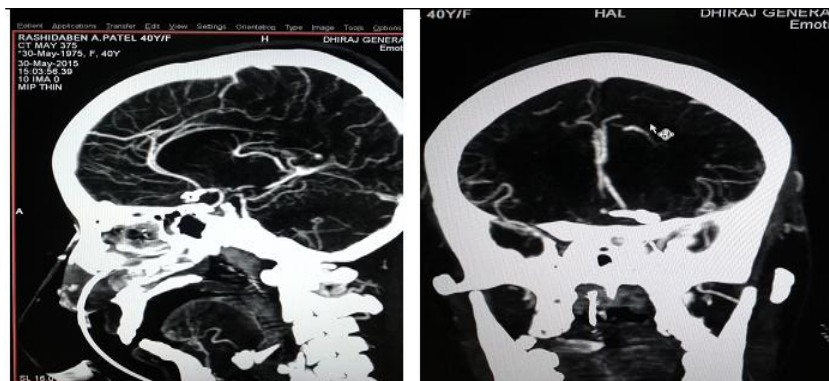


Figure 5: POST OPERATIVE CT ANGIOGRAPHY

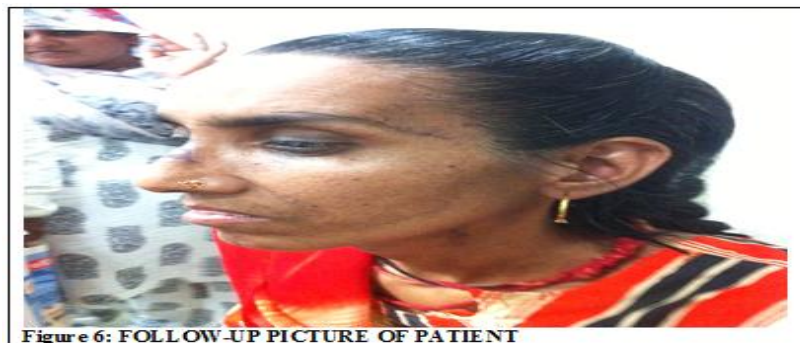

Figure 6: FOLLOW-UP PICTURE OF PATIENT

### Bibliography

- [1]. Reisch R, Perneczky A: Ten-year-experience with the supraorbital approach through an eyebrow skin incision. *Neurosurgery*. 2005 Oct;57:242-255.
- [2]. Mitchell P, Vindlacheruva RR, Mahmood K, Ashpole RD, Grivas A, Mendelow AD. Supraorbital eyebrow micranotomy for anterior circulation aneurysms. *SurgNeurol* 2005;63:47-51.
- [3]. Perneczky A, "Planning strategies for the suprasellar region: philosophy of approaches," *Neurosurgeon*. 1992;343-348.
- [4]. Reisch R, Perneczky A, Filippi R. Surgical technique of the supraorbital key-hole craniotomy. *Surg Neurol*. 2003 Mar;59(3):223-227.
- [5]. Ormond DR, Hadjipanayis CG. The Supraorbital Keyhole Craniotomy through an Eyebrow Incision: Its Origins and Evolution. *Minim Invasive Surg*. 2013:296469.
- [6]. Dare AO, Landi MK, Lopes DK, Grand W. Eyebrow incision for combined orbital osteotomy and supraorbital micranotomy: application to aneurysms of the anterior circulation. Technical note. *J Neurosurg*. 2001 Oct;95(4):714-718.
- [7]. Bhatoe HS. Transciliary supraorbital keyhole approach in the management of aneurysms of anterior circulation: Operative nuances. *Neurol India*. 2009 Sep-Oct;57(5):599-606.
- [8]. Czirják S, Nyáry I, Futó J, Szeifert GT. Bilateral supraorbital keyhole approach for multiple aneurysms via superciliary skin incisions. *Surg Neurol*. 2002 May;57(5):314-323.
- [9]. Veznedaroglu E, Benitez RP, Rosenwasser RH. Surgically treated aneurysms previously coiled: Lessons learnt. *Neurosurgery* 2004;54:300-303.